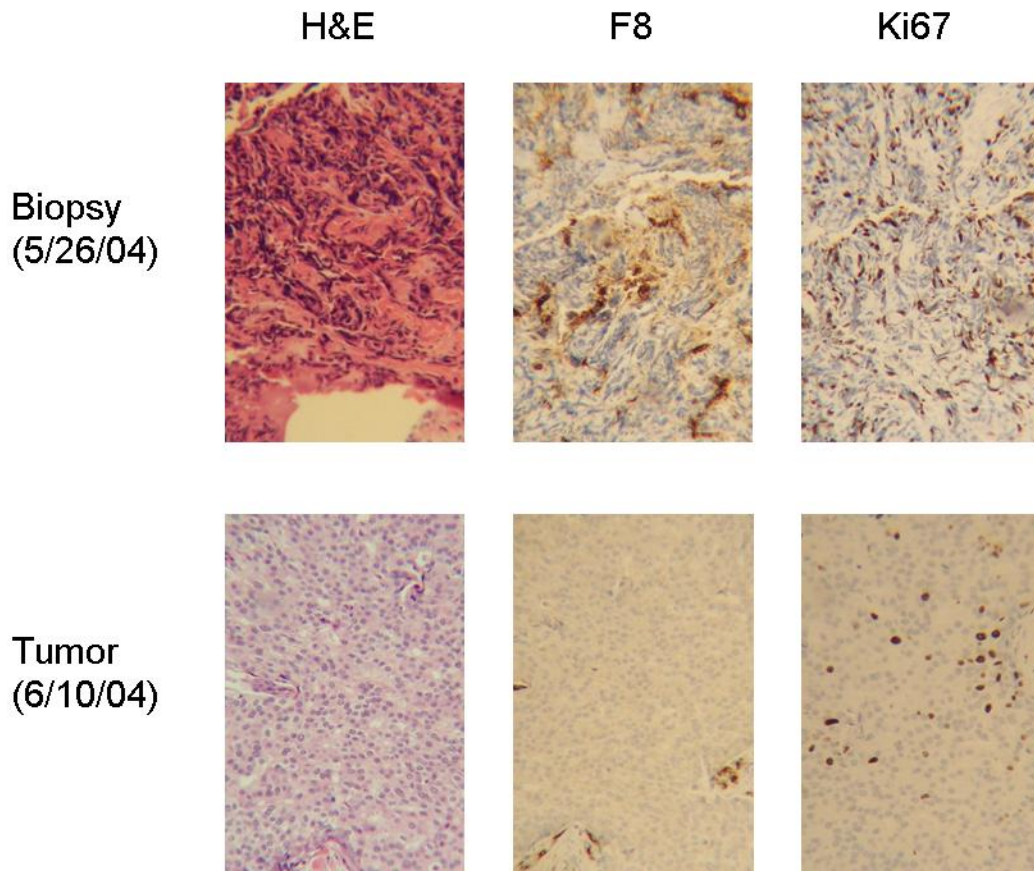


**REDUCTION OF ANGIOGENESIS AND CELL DOUBLING:
Invasive Ductal Carcinoma of the Mammary Gland
After**

16 days of Fermented Soy
By Karen McCarron, MD and Regina Chorsky, DO



Legend: Karen McCarron, MD and Regina Chorsky, DO: 28 year old female with a 2 cm invasive ductal carcinoma. F8 delineates vascularity and Ki67 is a proliferation marker. Top row (left to right) Biopsy: H&E; Immunohistochemistry F8; Ki67; Bottom row Tumor after taking fermented soy for 16 days (left to right): H&E; Immunohistochemistry F8; Ki67: Acknowledgement Haelan 951 fermented soy and Terry Nelson, technical support. Magnification 100X.